NOTE XXII.

ON DEFORMITIES OF THE HEAD IN SALMONIDAE.

BY

Dr. Th. W. van LIDTH de JEUDE.

(Plate 7).

In the »Verhandlungen der k. k. zoologisch-botanischen Gesellschaft in Wien" (Jahrg. 1863) Dr. Steindachner describes 3 monstrous heads of carps, presented to the Museum of Vienna, and suggests that these monstrosities could not be the results of some former wound, but that the deformity was caused by the pathological state of some part of the skull.

In Isid. Geoffroy St. Hilaire's interesting researches on teratology 1) we see on plate 1 (fig. 4, 5 and 6) three drawings of carp-heads, that bear a great resemblance to the figures of Dr. Steindachner's. According to the author these anomalies are not very rare in France, at those places where carps are cultivated in ponds; and Otto 2) also states the appearance of such monstrosities in Silesia.

In other fishes these deformities seem to be much rarer.

In Vrolik's Atlas 3) a pike is figured having the face and the upper-jaw but slightly developed, and consequently the under-jaw very prominent.

A similar drawing is to be found in Otto's Atlas of

---

1) Is. Geoffroy St. Hilaire, Histoire générale et particulière des anomalies de l'organisation chez l'homme et les animaux. Paris, 1832.

2) Otto, Lehrbuch der pathologischen Anatomie.

3) Tabulae ad illustrandum embryogenesin hominis et mammalium tam naturalem quam abnormam, auctore W. Vrolik. Amstelodami, 1849. Tab. 61, fig. 6.

monstrosities[1]. Sandifort[2] mentions a monstrous salmon-head, but neither figures nor describes it.

The latest researches of Dareste and Gerlach have more and more fixed the attention on teratological forms, and therefore I hope it will not be without interest, when I give here the description and the figures of 2 monstrous Salmonidae, that were presented to the Leyden Museum.

The first is a specimen of the salmon-trout (*Salmo trutta*) captured in our rivers in the month of October 1884. It is an unripe male of 25 cm. length, in a very wholesome condition, but with a deformity of the head, which is figured on pl. 7, fig. 1.

The prenasal portion of the head is but slightly developed and therefore the normal under-jaw projects in front of the snout. The praomaxillaria are small, and asymmetrically developed, the right one being the largest and bearing 4 teeth, the left one smaller with only 3 teeth. These praemaxillaria are not directed forwards, but curved, and each growing towards its fellow; therefore the head gets a short and broad appearance. The two bones do not meet at the midline but are connected by a cartilagenous strip. This strip is 4 m.m. broad, and shows at the underside a rounded emargination, giving to the snout some resemblance with a hare-lip. The supra-maxillaria are a little shorter than in the normal state, slightly curved and bearing small teeth, which are directed inwards.

The second monstrosity is a specimen of *Salmo salar*, and was presented to the Leyden Museum by Messrs. ten Houten & de Raadt at Kralingsche Veer. The head is figured on pl. 7, fig. 2 and shows no shortening, but a curvature of the prenasal portion.

I suppose this deformity is caused by the slight development of vomer, parasphenoid and palatines. Because of the articulation that exists in *Salmo* between the supra-maxillaries and the palatines, the slight development of vomer, parasphenoid and palatines has hindered the supra-maxillaries in their growth and prevented them getting their normal length. The left supra-maxillary is the smaller and bears a few but very small teeth, the right one is somewhat larger and bears teeth, which are much more developed.

---

[1] Museum anatomiço-pathologicum Vratislaviense. Vratislaviae, 1841. Tab. 3, fig. 5.

[2] Sandifort, Museum anatomicum.

Ethmoideum and nasalia have not ceased growing at so early a period, and on account of the slight development of the base of the skull in this region, the prenasal portion of the head got crooked.

Therefore the upper surface of the snout got bent, first in a downward and then in a backward direction. The praemaxillaria, fully developed but directed backwards, are consequently lying under the palate.

The teeth of the praemaxillaria are fullgrown, but have their points directed upwards and forwards, due to the abnormal position of these bones.

This salmon was a ripe male, weighing 2,7 kg. and showing no extraordinary meagerness. Stomach and intestines were quite empty, as generally is the case with salmons caught in our rivers.

Leyden Museum, May 1885.

1.

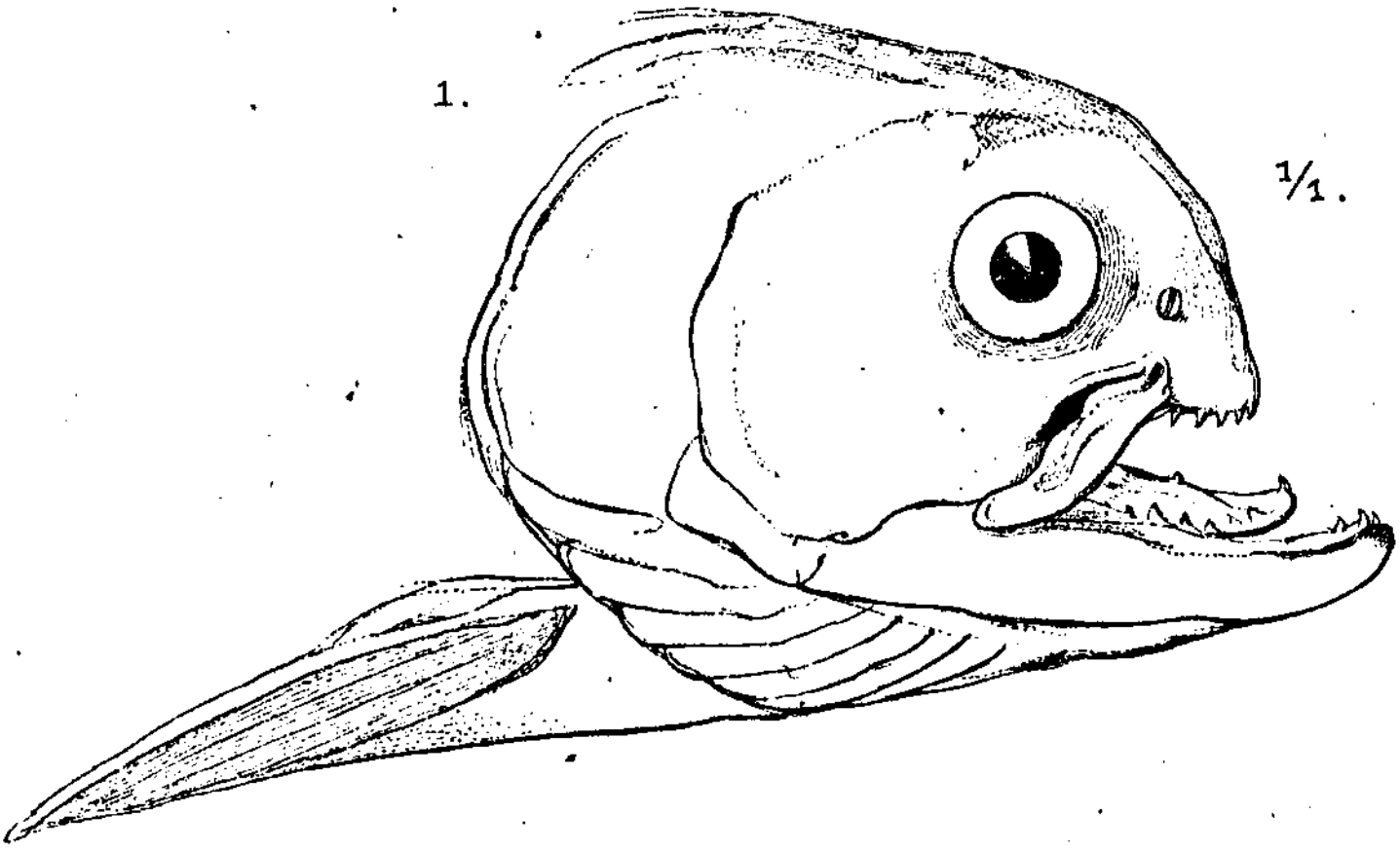

1/1.

2.

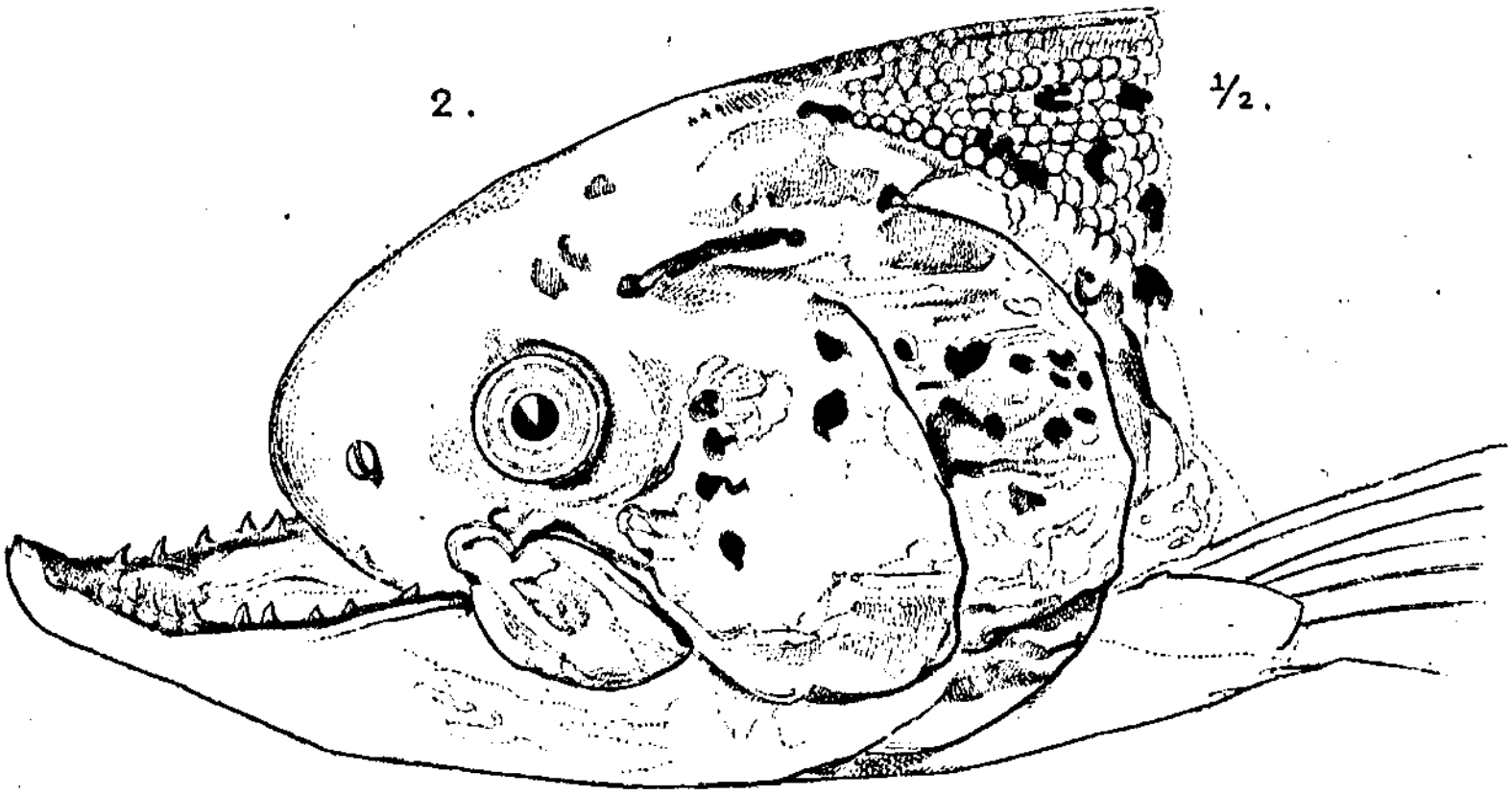

1/2.

H. Verlint ad nat. del. et lith.
P.W.M. Trap impr.

1. SALMO TRUTTA *Flem.*
2. SALMO SALAR *L.*